

A Study of the Shapes of Mandibular Lingula in North Coastal Andhra Pradesh

Durgesh.V¹, Roja Rani.Ch²

¹. Associate Professor, Department of Anatomy, Maharajah's Institute of Medical Sciences, Nellimarla, Vizianagaram, AndhraPradesh.

². Assistant Professor, Department of Anatomy, Maharajah's Institute of Medical Sciences, Nellimarla, Vizianagaram, AndhraPradesh.

Abstract: The lingular shapes in 40 (80 sides) adult mandibles of unknown sex are studied and classified into triangular, truncated, nodular and assimilated. 22 mandibles showed triangular type, 10 truncated, 7 assimilated and 1 nodular. There was a bilateral symmetry in all the mandibles.

Keywords: Lingula, mandibular foramen, inferior alveolar vessels and nerve

I. Introduction

The lingula is a sharp, triangular projection encroaching on the mandibular foramen through which the inferior alveolar vessels and nerve enter the mandible. It is situated on the inner aspect of the ramus of mandible and the sphenomandibular ligament is attached to it. Lingula's close proximity to the mandibular foramen and the inferior alveolar nerve make it an important landmark in certain surgical procedures like Sagittal Split Ramus Osteotomy (SSRO)¹. In this procedure, the horizontal Osteotomy is to be made just above the lingula and extended posteriorly to make a safe split to prevent nerve damage.^{2,3} The correct identification of lingula is also important in inferior alveolar nerve anesthesia. 29% to 35% of failures in this anesthesia are due to the variable shapes of lingula.^{4,5}

II. Materials And Methods And Results

40 adult mandibles of unknown age and sex are obtained from the Anatomy museum of Maharajah Institute of Medical Sciences and lingulae were photographed and classified.

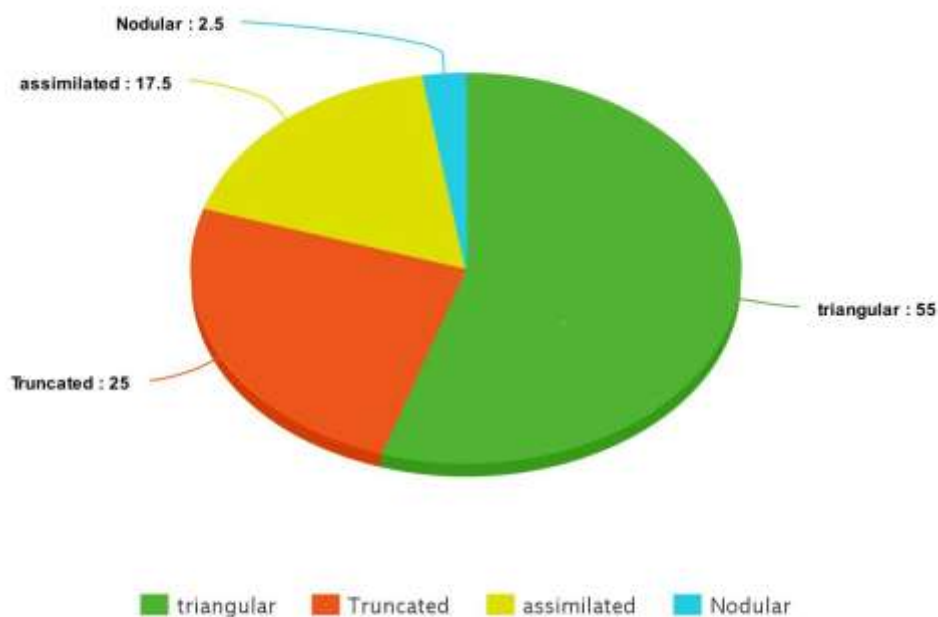
Results

22 lingulae are triangular in shape (55%)

10 lingulae are truncated (25%)

7 lingulae are assimilated (17.75%)

1 lingula is nodular (2.5%)



III. Discussion

Lingula, a Latin word for ‘ little tongue’ was first described in Johannes-Baptist Spix in 1815 and was therefore named Spix’s ossicle or ‘spine’.⁶

Lingulae are classified into triangular, truncated, nodular and assimilated depending on their shape.⁷ The triangular type presents an apex directed upwards or backwards, with an anterior border and a posterior. The truncated type presents an upper border which is horizontal (may be notched). The nodular type is an almost imperceptible lingula and assimilated type fuses with the ramus and gives an appearance of absence of lingula. Lingula also shows variation in gender and race. The triangular and assimilated types were the most and the least prevalent both in males (67±90% and 5±0% respectively), and in females (70±6% and 4±4% respectively). The truncated type was twice as common in males (17±6% sides) as in females (8±8%), while the nodular type was a little less than double in females (16±2%) as compared with males (9±6%)⁷. A study on Thai population the truncated shape occurred most commonly (47.2%) followed by the nodular (22.9%), triangular (16.7%) and assimilated shapes (13.2%).⁸ One study in Indian population showed nodular variety of lingula was the most common type which was followed by the truncated, the triangular and the assimilated type on 50 dry mandibles, respectively.⁹ In a retrospective study performed in Turkish population using cone beam computed tomographic images, nodular type (51.2%) of the lingula was most commonly found and the least common was the assimilated type (2.7%), truncated and triangular varieties were present in 32% and 14.1% of the mandibles, respectively. In our study we found that triangular type is most frequent followed by truncated and assimilated and nodular is the least.

IV. Conclusion

The lingula and sphenomandibular ligament develop from the Meckel’s cartilage. Knowledge of variations in the shapes of lingula can be of use in maxilla facial surgery and inferior alveolar nerve blocks.

References

- [1]. M.S.Monnazi,L.A. Passeri, M.F.R.Gabrielli.P.D.A.Bolini Anatomic study of the mandibular foramen,lingula,antilingula in dry mandibles and its statistical relationship between the true lingula and antilingula. *International Journal of Oral and Maxillofacial Surgery*,vol.41,no.1,pp.74-78,2012.
- [2]. G.Salgado,H.Oscar inzunza,M.Cantinet al., ‘Evaluation of mandibular Anatomy related to sagittal split ramus Osteotomy” *International Journal of Morphology*,vol.30,no.1,pp.30-39,2012.
- [3]. B.N.Epker, ‘Modifications in the sagittal osteotomy of the mandible” *Journal of oral Surgery*,vol.35,no.2,pp.157-159,1977.
- [4]. W.D.Robertson, ‘Clinical evaluation of mandibular conduction anaesthesia” *General Dentistry*,vol.27,no.5,pp 49-51,1979.
- [5]. T.P.Levy, “An assessment of the Gow-Gates mandibular block for the third molar surgery,” *the Journal of American Dental Association*, vol, 103, no.1, pp.37-41, 1981.
- [6]. Dobson. J (1962) *Anatomical Eponyms*, 2nd edn, p. 194. Edinburgh, London: E. & S. Livingstone
- [7]. A. Tuli , R. Choudhry , S. Choudhry , S. Raheja and S. Agarwal. (J. Anat. (2000) 197, pp. 313–317, with 7 figures Printed in the United Kingdom
- [8]. Jansisyant P, Apinhasmit W, Chompoopong S (2009) Shape, height and location of the lingual for sagittal ramus osteotomy in Thais. *Clin Anat*, 22: 787–793.
- [9]. Shenoy V, Vijayalakshmi S, Saraswathi P (2012) Osteometric analysis of mandibular foramen in dry human mandibles. *J Clin Diagn Res*, 6: 557–560.
- [10]. Sekerci AE, Sisman Y (2014) Cone-beam computed tomography analysis of the shape, height, and location of the mandibular lingula. *Surg Radiol Anat*, 36: 155–162.
- [11]. Keith LM and Persaud TVN. *The Developing Human-Clinically oriented embryology*, 2003, 7th edition, p.204. Saunders :Elseviers



Fig.1. Triangular with only an anterior border



Fig.2. Typical triangular with apex, anterior and posterior borders



Fig.3. truncated with a clear upper border



Fig.4. Truncated with a notch on the upper border



Fig.5 Assimilated

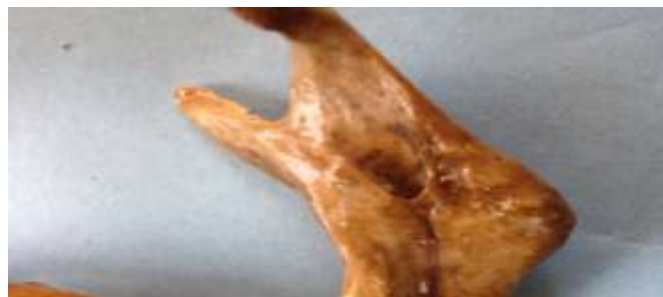

Fig.6 Nodular (a less prominent lingula)